

Arthroscopic Matrix-based Meniscus Repair – AMMR™ using the Chondro-Gide® Membrane



Tomasz Piontek, MD, PhD

Dr. Tomasz Piontek graduated from the Medical Academy Poznan, Poland and specialized in orthopedics and traumatology. He works at the Rehasport Clinic, Poznan – a FIFA Medical Center of Excellence since 2014.

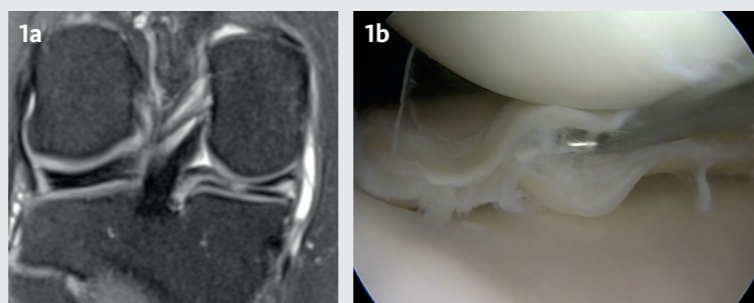
Dr. Piontek pioneered the development of surgical techniques towards repair of cartilage and healing of damaged meniscus that are based on AMIC® and Chondro-Gide®, respectively. His approach to treatment is holistic. In order to optimize treatment and patient outcomes, he works closely with physiotherapists and other specialists. He also leads the medical teams of two football clubs.

As a surgeon and researcher with a focus on sports medicine, he developed the AMMR™ technique described in this indication sheet. Based on a concept of Roland Jakob to preserve the meniscus, Piontek wraps the meniscus with the Chondro-Gide® membrane and injects bone marrow blood into the resulting space.

Dr. Piontek has authored several publications in the field of cartilage and meniscus repair and trains doctors internationally for arthroscopic surgery in the knee, ankle, and hip.

Memberships

- > Polish Orthopaedic & Trauma Society
- > Polish Arthroscopic Society
- > Polish Society of Sports Traumatology
- > ESSKA / ISAKOS / ISHA / ESSKA-AFAS



Pre-operative MR (Fig. 1a) and arthroscopic image (Fig. 1b) of a complex horizontal posterior horn tear of the medial meniscus.



Geistlich Pharma AG
Headquarters Switzerland
Business Unit Surgery
Bahnhofstrasse 40
CH-6110 Wolhusen
Tel. +41 41 492 55 55
Fax +41 41 492 67 35
surgery@geistlich.com
www.geistlich-surgery.com

Materials Used:

- > General knee arthroscopy instruments
- > Chondro-Gide® membrane, 20 x 30 mm (Geistlich Pharma)
- > Spiked clamp for insertion of membrane (Aesculap Chifa, B. Braun)
- > Halfpipe cannula (Arthrex)
- > Non-absorbable all-inside meniscal sutures:
 - > Knee Scorpion™ Suture Passer (Arthrex)
 - > FAST-FIX® 360 Meniscal Repair System (Smith & Nephew)
- > Non-absorbable inside-out meniscal sutures:
 - > Zone-specific cannula (Arthrex)
 - > Meniscal repair needles with FiberWire® # 2-0 (Arthrex) or ETHIBOND EXCEL™ 0 (Ethicon)
 - > Needle catcher (Arthrex)
- > Bone Marrow Biopsy Needle (PICK UP, Gauge 11, MDL Srl.)

Articles by the author related to the topic:

- > Cierniewska-Gorzela K, Bąkowski P, Naczki J, Jakob R, Piontek T. Complex Meniscus Tears Treated with Collagen Matrix Wrapping and Bone Marrow Blood Injection: Clinical Effectiveness and Survivorship after a Minimum of 5 Years' Follow-Up [published online ahead of print, 2020 Jun 1]. *Cartilage*. 2020 Jun 1; 1947603520924762. doi: 10.1177/1947603520924762.
- > Piontek T, Cierniewska-Gorzela K, Naczki J, Jakob R, Szulc A, Grygorowicz M, Słomczykowski M. Complex Meniscus Tears Treated with Collagen Matrix Wrapping and Bone Marrow Blood Injection: A 2-Year Clinical Follow-Up. *Cartilage*. 2016 Apr;7(2):123-39. doi: 10.1177/1947603515608988.
- > Piontek T, Cierniewska-Gorzela K, Szulc A, Słomczykowski M, Jakob R. All-arthroscopic technique of biological meniscal tear therapy with collagen matrix. *Pol Orthop Traumatol*. 2012 Jul 31;77:39-45.

Arthroscopic Matrix-based Meniscus Repair – AMMR™ using the Chondro-Gide® Membrane

CLINICAL PROBLEM

CLINICAL PROBLEM

Since meniscectomy can have detrimental long-term effects on a patient's knee function and quality of life, saving the meniscus rather than resecting it is of utmost importance to Dr. Piontek. The AMMR™ treatment described in this indication sheet enabled the preservation of the damaged meniscus and supported an effective repair and healing process.

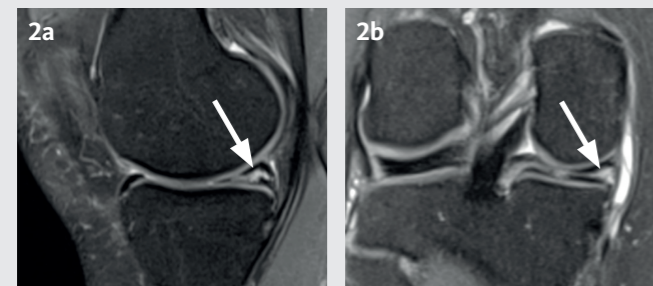
MEDICAL HISTORY AND DIAGNOSIS

A 35-year-old male experienced a skiing injury to his right knee approximately 2 years ago. The pre-operative physical exam revealed symptoms of pain and joint line tenderness, effusion, episodes of locking, and a positive McMurray's test (presence of Barrett criteria).

Pre-operative Lysholm and IKDC 2000 Subjective Scores were 70 and 39 points, respectively.

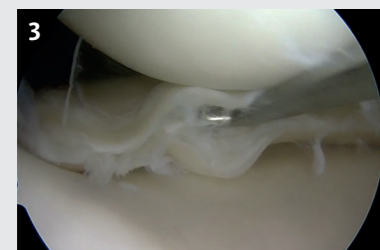PRE-OPERATIVE IMAGING

On sagittal (Fig. 2a) and coronal (Fig. 2b) MR images, a horizontal tear in the posterior horn of the right medial meniscus extending into the free edge (white arrows) was detected.



Meniscal lesion

The arthroscopic inspection ruled out concomitant pathology but showed a complex horizontal tear in the posterior horn of the medial meniscus (Fig. 3).

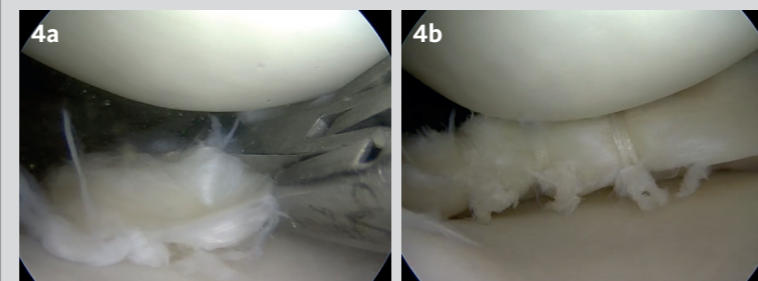


TREATMENT

STEP-BY-STEP SURGICAL TECHNIQUE

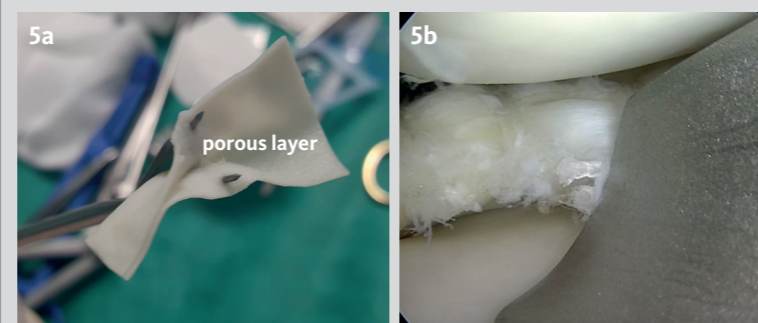
Suturing the torn meniscus

After loose tissue had been removed, the displaced meniscus fragments were reduced and the tear size was measured. The torn meniscus was sutured using an all-inside technique (Fig. 4a) to restore a stable rim (Fig. 4b).



Insertion of the Chondro-Gide® membrane

The Chondro-Gide® membrane was hydrated using sterile saline directly in the tray of the inner sterile blister. It was then mounted on a clamp with spiked jaws with the porous layer of the membrane facing inward (Fig. 5a). The loaded clamp was introduced into the joint through the arthroscopic portal and with the aid of a "halfpipe" cannula (Fig. 5b).

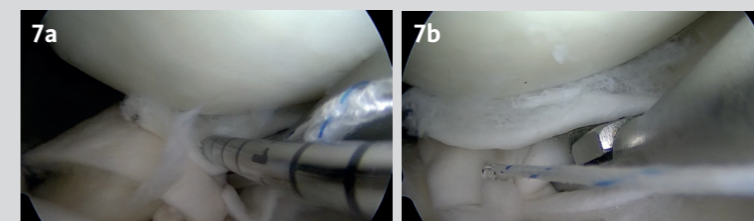


Mounting the membrane in the correct orientation ensured that the porous layer remained facing the meniscal surface while the compact layer faced the articular surfaces of femur and tibia (Fig 6).



Fixation of the membrane to the meniscus

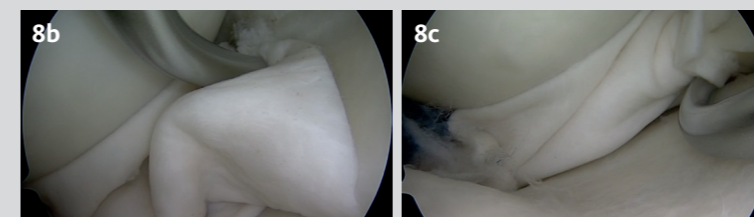
The membrane was held in place with a clamp to allow its fixation to the native meniscus at the most posterior aspect using an all-inside suture (Fig. 7a & b).



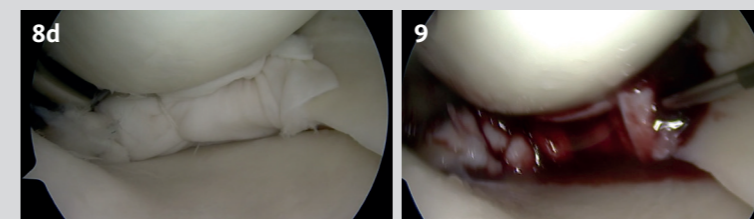
The clamp was removed and the membrane manipulated into position with an arthroscopic probe (Fig. 8a) so that the area with the torn meniscus tissue was covered.



Next, the anterior aspect of the membrane was fixed to the superior (Fig. 8b) and inferior (Fig. 8c) meniscus surface using inside-out sutures.



Additional sutures were placed along the membrane's length in order to enclose the damaged tissue and securely fix the membrane (Fig. 8d).



Addition of bone marrow blood to enhance healing

Bone marrow blood was aspirated from the intercondylar notch using a bone marrow biopsy needle. Approximately 5 ml were injected between membrane and meniscus under direct vision in "dry arthroscopy" (Fig. 9). Note: when choosing the biologic factor to enhance healing (e.g. bone marrow blood), local regulatory guidelines have to be respected.

FOLLOW-UP

The surgery was completed by closing the wounds and without a drain. Thrombosis prophylaxis with low molecular weight heparin was prescribed until full weight-bearing.

Post-operative rehabilitation

The rehabilitation protocol was similar to the one used for meniscus suture repair. During the initial 4 weeks, the patient used crutches for partial weight-bearing and a hinged brace to limit knee flexion. After about 8 weeks, return to full weight-bearing and full range of motion was allowed. Return to sports was allowed after full recovery (approx. 6 months).

AFTER 2 YEARS

2 years after AMMR™ treatment, the patient experienced no symptoms of pain, effusion or locking, and a negative McMurray's test (absence of Barrett criteria).

Clinical scores were excellent. The Lysholm score improved from 70 to 97 points and the IKDC 2000 Subjective Score from 39 to 93 points, respectively.

Imaging

Sagittal (Fig. 10a) and coronal (Fig. 10b) MR images showed inhomogeneous tissue (white arrows) but no signs of effusion and meniscus extrusion, and no evidence of cartilage damage indicating a normal healing process.

